

CLINICAL EVALUATION AND INVESTIGATION OF NEUROPATHY

Hugh J Willison, John B Winer

ii3

J Neurol Neurosurg Psychiatry 2003;74(Suppl II):ii3-ii8

The assessment and investigation of a possible neuropathy is one of the most common clinical problems facing the general neurologist. Studies of the prevalence of neuropathy in the community are rare but suggest a figure of between 2–8%,¹ making peripheral neuropathy at least as common as stroke. Despite this high prevalence of neuropathy, it is only a small proportion of patients with neuropathies who are referred for detailed evaluation, principally those individuals with disabling disease, or with none of the obvious risk factors such as diabetes or alcoholism.

A logical approach to the assessment of such patients is essential and can be organised into a number of basic questions. The neurologist faced with a patient with a neuropathy has to deal with literally thousands of possible causes, many extremely uncommon, and these can only be simplified by defining the neuropathy by other features that lead to the select few of most likely diagnoses. This is in part a process of pattern recognition but can be helped by a stepwise approach. Several algorithms² and review articles³ have been published to aid this process and a typical one has been constructed here (fig 1).

The approach adopted in this article is to present the evaluation as a list of commonly asked questions that, if correctly addressed and answered, are likely to yield diagnostically important information, and hence direct appropriate management. This is not intended as an exhaustive account of neuropathy but is a personal view, illustrative of a diagnostic process that is commonly adopted.

DOES THE HISTORY AND EXAMINATION SUGGEST THAT THE PATHOLOGICAL PROCESS IS LOCALISED TO THE PERIPHERAL NERVE?

This question can usually be answered easily, but occasionally patients may present unusually, and multiple pathologies may confound the diagnostic process. Spinal cord disease is one of the most common differential diagnostic considerations in patients with neuropathic-type symptoms (box 1). Where sensory symptoms are present with few clinical signs, the classical features of a lower motor neurone disorder may be absent and a transverse myelitis, myelopathy, or other central nervous system disorder can masquerade as a neuropathy. Involvement of cranial nerves (for example, facial numbness or weakness, oculomotor disturbance) in an acute inflammatory neuropathy is helpful in excluding a cord lesion with a pseudo-lower motor neurone pattern of presentation, as may occur in acute myelopathies.

A common co-occurrence, particularly in the elderly, is the combined presence of cervical spondylotic myelopathy and late onset predominantly sensory axonal neuropathy. In the same context, spondylotic radiculopathies may co-occur with upper limb entrapment neuropathies. In these circumstances, experience and care is required to identify the dominant pathological process, and this may not always be possible. Certain neuropathies co-exist with CNS disease, such as vitamin B12 deficiency, adrenomyeloneuropathy, neuroacanthocytosis, spinocerebellar syndromes, to name but a few of many. In these situations there is no substitute for pattern recognition and, if this fails, a structured approach, both of which are more likely to succeed than random investigation.

HAS THE PRESENTING COMPLAINT BEEN FULLY DESCRIBED?

It is surprising how often simple, clearly discernable features of the history can be overlooked. This is particularly the case in inherited neuropathies and congenital syndromes. Funny feet, unevenly worn shoes, and childhood and adolescent clumsiness, especially in sports and tasks requiring fine coordination, are all important clues to an illness that may extend back well beyond the duration of the patient's more obvious symptoms.

The duration of symptom development is important to define and the following categories are used as broad guidelines in neuropathy circles: acute (< 4 weeks), subacute (1–3 months), and chronic (> 3 months). Vasculitic lesions are often hyperacute mononeuropathies, usually coming on over 24–72 hours. In some circumstances, such as early assessment following symptom onset,

See end of article for authors' affiliations

Correspondence to:
Professor Hugh J Willison,
Division of Clinical
Neurosciences, Southern
General Hospital, Glasgow
G51 4TF, UK;
h.j.willison@udcf.gla.ac.uk

Box 1: Diagnostic pitfalls in establishing a neuropathy

- ▶ Transverse myelitis
- ▶ Hypokalaemia
- ▶ Spinal arteriovenous malformation
- ▶ Conus tumour
- ▶ Carcinoma prostate

ii4

this cannot be clarified at presentation but becomes evident later. Guillain-Barré syndrome (GBS), for example, by definition reaches its nadir within four weeks of onset, and any progression beyond this may suggest relapsing disease or evolution into chronic inflammatory demyelinating polyradiculoneuropathy (CIDP), both of which would require further treatment. A frequent difficulty in the history is encountered in separating residual deficit following an acute event, from a chronic process. The time course helps to limit the differential diagnosis, especially for acute and chronic demyelinating syndromes (box 2).

One often undervalued aspect of clinical history taking relates to the precise details of the site and character of sensory symptoms. Detailed accounts of this are available from many sources.⁴ Focal symptoms can provide vital clues to individual nerve or root disorders, that in themselves may be sufficient to make a firm diagnosis of, for example, meralgia parasthetica. Distal dying back axonopathies have a very characteristic length dependent pattern of symptom evolution, that is usually symmetrical, affecting feet, then hands, then anterior trunk. Demyelinating neuropathy may also have a length dependent pattern of sensory evolution because in a diffuse process longer fibres have a higher probability of becoming blocked. In contrast, multi-segmental patterns of sensory involvement, including the trunk, suggest dorsal root ganglionopathies as may occur in the neuropathy of Sjogren's syndrome, for example.

Apart from the site of onset, the character of sensory symptoms needs to be pinned down from the history, as it is often poorly described by patients and can be diagnostically useful. Pain, loss of temperature appreciation, and autonomic symptoms are all features of selective small fibre involvement. The negative sensory symptom of unsteadiness that is more prominent in the dark, or on eye closure, is characteristic of sensory ataxia caused by large fibre involvement. These patterns of sensory involvement do not localise the lesion,

Box 2: Demyelinating neuropathies

- ▶ Acute
 - Guillain Barre syndrome (GBS)
- ▶ Chronic
 - chronic inflammatory demyelinating polyradiculoneuropathy (CIDP)
 - paraproteinemia related
 - amiodarone toxicity
 - Refsum's disease
 - Charcot-Marie-Tooth (CMT) types 1, X and AR CMT 1
 - metachromatic leucodystrophy
 - statins

even to peripheral nerve, but they do give an indication of fibre type involvement, and hence narrow down the likely causes.

HAVE I OBTAINED ADEQUATE PAST, FAMILY, OCCUPATIONAL, AND DRUG HISTORIES?

A very important consideration is to establish whether the neuropathy is an isolated illness of peripheral nerve, or whether it is occurring in the context of disease elsewhere, or other historical factors. Important background clues and information are often missed in the first round of assessment and only come to light retrospectively.

Concurrent systemic diseases are clearly important, particularly organ failure, endocrine disorders, and connective tissue disease. Diabetes, and latent diabetes, should always be sought. The detailed family history is often crucial, even if negative, provided that the family is of a sufficient size to be informative. This may include an opportunistic examination of accompanying relatives, even if restricted to tapping the ankle jerks, or recording a lower limb motor conduction velocity.

Toxic exposure in the workplace is becoming less prominent a risk factor as industrial environments improve. Thus lead, arsenic, acrylamide, and volatile solvents are all rare as causes of neuropathy. However, a drug history is crucial, both prescribed and recreational. The list of prescribed medications resulting in neuropathy is too long to list, major culprits being amiodarone, phenytoin, statins, many antibiotics, and chemotherapies: if in doubt, look it up in your BNF! Abused drugs provide a twofold risk: the drug itself—for example, tobacco (paraneoplastic), alcohol (toxic), cocaine (vasculitic)—and

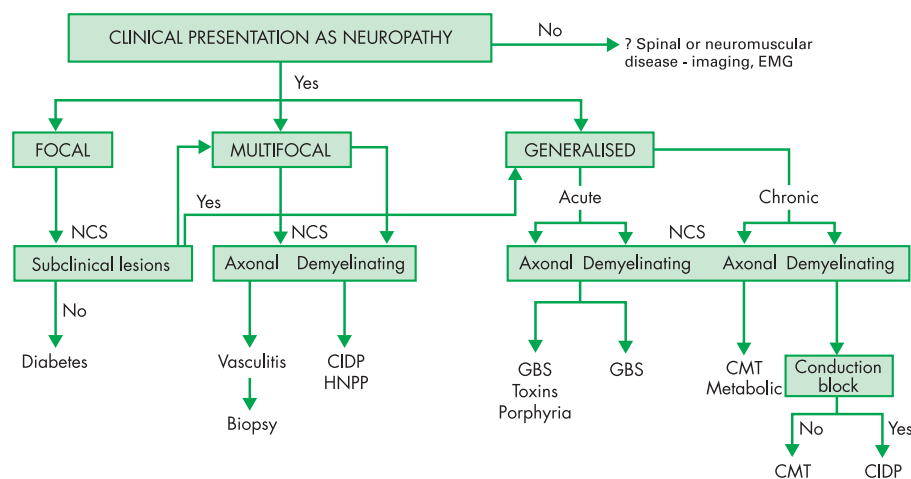


Figure 1 Algorithm showing a stepwise approach to the assessment and investigation of a possible neuropathy. CIDP, chronic inflammatory demyelinating polyradiculoneuropathy; CMT, Charcot-Marie-Tooth; EMG, electromyography; GBS, Guillain-Barré syndrome; HNPP, hereditary neuropathy with liability to pressure palsies; NCS, nerve conduction studies.

the behaviour related consequences, including HIV or hepatitis C infection, and nutritional deficiency.

Within the ethnic diversity and globalisation of travel seen in multiracial Britain, certain types of neuropathy may be more prominent in particular groups. There is no point suspecting a Scottish highlander of having leprosy, but he may have acquired neuroborreliosis locally, or have returned with it from a walking tour of the Black Forest. The contrary applies to an immigrant from India, leprosy being one of the most common causes of neuropathy worldwide. Vegans are vulnerable to nutritional deficiency; intrafamilial marriages throw up recessive neuropathies.

WHAT SPECIAL FEATURES OF DIAGNOSTIC HELP MIGHT I PICK UP FROM THE EXAMINATION?

We all know of the apocryphal stories of the eager specialist registrar who leaves the urine pot on the windowsill to diagnose porphyria. However, picking up special diagnostic features from the general examination is not easy to approach systematically, and often it requires a return visit to the patient to seek something other tests might lead you to suspect. Thus the umbilical keratomas of Fabry's disease, the Mees lines of arsenic toxicity, and the orange tonsils of Tangier's disease are but a sprinkling of the rarified diagnostic opportunities available to the well tutored.

Certain aspects of the peripheral nerve examination are more practically useful. Convention dictates that we start with the cranial nerves. Thus anosmia occurs in Refsum's disease and B12 deficiency; optic atrophy when not associated with mixed central and peripheral demyelinating disease may suggest an inherited syndrome. Anisocoria and impaired pupillary light reflexes indicate parasympathetic damage and may be isolated, as in Adie's syndrome, or direct a more careful search for autonomic involvement elsewhere, as may occur in diabetic neuropathy or the acute dysautonomia occasionally seen in the GBS spectrum. Impaired ocular mobility suggests botulism or Miller Fisher syndrome, facial weakness is a frequent feature of GBS, and trigeminal sensory loss of Sjogren neuropathy. Lower cranial nerve palsies are typical of Kennedy's disease, which along with gynaecomastia will allow you to make a confident bedside diagnosis when confronted with a case of diffuse motor neuronopathy.

Assessing muscle strength is conventionally conducted using the Medical Research Council scale and nothing has superseded this despite the uncomfortably broad range of power in band 4. This is not a shortcoming of the design of the scale which originated in 1941 for assessing the severe nerve injuries sustained in military combat, but a pleasant reminder that today we tend to complain about smaller things than our predecessors. Dynamometry can be used for the more precise measurements needed for clinical trials or for assessing responses of individual muscle groups to treatment, such as intravenous immunoglobulin (IVIg) in multifocal motor neuropathy (MMN).

However recorded, power measurement is important to conduct and record properly and distribution of weakness is crucial to diagnosis. A broad knowledge of peripheral nerve territories and root values is our neurological bread and butter. Difficulties can arise when multiple mononeuropathies become confluent since they can be hard to separate from polyneuropathies, and when examining complex brachial and lumbar plexus lesions. Electrophysiological help is often required in these situations. The medical student view that weakness in polyneuropathy is invariably distal also rarely

Box 3: Focal and multifocal neuropathies

- ▶ Entrapment neuropathy—for example, carpal tunnel syndrome (CTS), ulnar nerve at elbow, common peroneal nerve over fibular head
- ▶ Myxoedema, acromegaly
- ▶ Amyloid
- ▶ Diabetes
- ▶ Hereditary neuropathy with liability to pressure palsies (HNPP A)
- ▶ Vasculitis
- ▶ Multifocal motor neuropathy

ii5

proves true in modern practice. In length dependent axonopathies, such as Charcot-Marie-Tooth 2 (CMT 2) or metabolic neuropathies, this may be the case. Demyelinating neuropathy, such as GBS and CIDP, is often characterised by proximal dominant weakness, since multiple roots are often affected by conduction block, and may even produce a "pseudo-pyramidal" pattern of weakness.

The examination hallmark of neuropathy is to elicit the tendon reflexes. Focal reflex loss with preservation at other sites has clear implications. Distal reflex loss, manifested by absent ankle jerks but preserved reflexes elsewhere, is very characteristic of the length dependent axonopathies. In the acquired demyelinating neuropathies, reflex loss is usually generalised, as is also usually the case in CMT 1.

The sensory examination is best approached by testing modalities that subservise large fibre (vibration sense and proprioception) and small fibre (pinprick, pain, and temperature) function, in conjunction with a consideration of both focal and length dependent features, since this can provide key clues to the likely cause. Sensory examination must be approached with a clear diagnostic purpose and guided by knowledge of the major cutaneous nerve and root patterns, otherwise it is likely to be unrewardingly circumspect.

IS THE NEUROPATHY FOCAL, MULTIFOCAL OR GENERALISED?

The pattern of distribution of peripheral nerve involvement is very helpful in reaching a diagnosis. Thus mononeuropathies, especially if an entrapment site, are often an isolated phenomenon, possibly related to pregnancy, thyroid disease or occupation, but importantly may also occur as features of a more generalised disorder, such as hereditary neuropathy with liability to pressure palsies (HNPP) or amyloidosis. Mononeuropathies occurring outside entrapment sites are more important to investigate fully, especially if vasculitis is suspected as this needs careful evaluation for treatment. If the pattern suggests a single nerve or plexus lesion at an unusual site of compression or invasion, such as a radial nerve lesion compressed on a chair in a patient following an overnight binge, or invasion of the brachial plexus with breast malignancy, this is clearly important to detect. The list of possible causes for focal or multifocal neuropathies is considerably reduced compared with generalised neuropathies (box 3). Another issue is to consider whether the neuropathy involves upper or lower limbs in a preferential pattern. Most length dependent axonopathies will commence in the legs, but occasionally inherited neuropathies and neuronopathies begin in the hands in some families. In hereditary amyloid neuropathies, the hands are often affected early. In acquired demyelinating neuropathies, the arms may be prominently

Box 4

- ▶ Predominantly sensory neuropathies
 - diabetes
 - thiamine deficiency
 - malignancy
 - leprosy
 - hereditary sensory neuropathies
 - amyloid
 - uraemia
 - sarcoid
- ▶ Predominantly motor neuropathies
 - Guillain-Barre syndrome and CIDP
 - porphyria
 - diphtheria
 - botulism
 - lead
 - Charcot-Marie-Tooth

affected to a greater extent than would be expected from the degree of involvement in the legs.

WHAT IS THE RELATIVE EXTENT OF MOTOR AND SENSORY NERVE INVOLVEMENT?

It is clear that some neuropathy syndromes are purely motor, such as multifocal motor neuropathy with conduction block (MMNCB), whereas others are purely sensory, such as a subacute sensory neuronopathy (SSN) caused by paraneoplastic or other autoimmune dorsal root ganglionopathies (box 4). However, clinical life is rarely so simple and the majority of neuropathies are mixed, if not symptomatically, then at least on clinical or electrophysiological examination. Even in MMNCB, some very minor sensory symptoms or signs (including electrophysiological) in motor affected territories are sometimes evident and should not exclude the diagnosis, although they may encourage one to consider the closely related syndrome, multifocal acquired demyelinating sensory and motor neuropathy (MADSAM, Lewis-Sumner syndrome). In contrast sensory involvement should never be the case in motor neuron disease (MND), and would cast serious doubt on this diagnosis. Similarly motor involvement should never occur in a pure dorsal root ganglionopathy; however, the neuropathy associated with anti-Hu antibody is not as uniform an SSN as text books state in that motor involvement can often be found in this patient group.³ Thus this question is intended as a helpful guideline to diagnosis rather than an immutable rule.

IS THERE PROMINENT SMALL FIBRE AND AUTONOMIC INVOLVEMENT?

Autonomic features, including pupillary, sweat gland, cardiovascular, and gastrointestinal involvement are features of diabetic and amyloid neuropathy, and can occasionally be prominent in GBS (box 5). This requires a careful history for symptoms of light intolerance, postural hypotension, nocturnal diarrhoea, impaired sweating, and bladder dysfunction. Examination can include careful analysis of pupillary light responses, lying and standing blood pressure measurement, and assessment of sinus arrhythmia with ECG measurement during deep breathing.

IS THE NEUROPATHY AXONAL OR DEMYELINATING ON CLINICAL GROUNDS?

This cannot be determined clinically with any degree of accuracy and requires neurophysiology with measurement of con-

Box 5: Small fibre and autonomic neuropathies

- ▶ Diabetes
- ▶ Amyloidosis
- ▶ Fabry's disease
- ▶ Tangier disease
- ▶ Hereditary sensory and autonomic neuropathies
- ▶ Chronic idiopathic small fibre sensory neuropathy
- ▶ Sjogren's syndrome

duction velocities in several nerves, assessment of conduction block, measurement of sensory action potentials, and measurement of distal latencies and F wave latencies, as described below.

However, there are some clinical clues that can be helpful. Widespread reflex loss, including in muscle groups that are not particularly weak or wasted, is more a feature of demyelination. In contrast, selective loss of the ankle jerks in the presence of distal wasting and weakness is more typical of an axonopathy, especially if accompanied by a stocking distribution of sensory loss.

Thus the complete assessment of a patient with a neuropathy might characterise the clinical syndrome as a chronic multifocal, predominantly motor, demyelinating neuropathy. This type of neuropathy would have a restricted differential diagnosis and would target investigations towards distinguishing CIDP from a paraproteinemia and amiodarone toxicity.

The largest and most difficult group is the mixed motor sensory neuropathy with a pattern to suggest a dying back axonopathy and confirmation of an axonal neuropathy on electrophysiology (box 6). Here a careful history is paramount with detailed enquiry into other systemic disease and a detailed family tree. Constructing a family tree may bring out details of forgotten relatives with stigmata of an inherited neuropathy such as high arched feet.

WHAT ADDITIONAL INFORMATION CAN I EXPECT FROM A NEUROPHYSIOLOGICAL ASSESSMENT?

Detailed consideration of this is outwith the scope of our introduction, but it is worth making a few points. The neurophysiological examination cannot be conducted in isolation from the clinical assessment, but has to be led by the historical and clinical findings. Many clinical electrophysiologists take a history and perform an examination before their electrophysiological studies in order to guide their choice of sites and testing methods, but this by necessity is often rather limited. It is therefore extremely helpful for the clinician to highlight the most pertinent questions sought from the laboratory, ideally by discussion or alternatively on the request form. In the latter case, the neurologist should succinctly specify the information required from the neurophysiological assessment of the patient, but should refrain from specifying the individual tests required to achieve that!

Sensory studies are often the first approach to determining the presence of a neuropathy. If objective sensory loss affecting large fibres is clinically evident, the presence of normally preserved sensory nerve action potentials (SNAPs) points away from the cause being distal to the dorsal root ganglion, and suggests a central or root disorder. Focal entrapments can often be readily picked up by side to side comparisons on sensory nerve examination. Length dependent large fibre neuropathies are characterised by disappearance of distal leg SNAPs (that is, superficial peroneal and sural nerve) before

Box 6: Chronic axonal neuropathies

- ▶ Drugs or toxins
 - alcohol
 - chemotherapeutic agents—for example, vincristine, cisplatin
 - organophosphate
 - phenytoin
 - antibiotics—for example, metronidazole, dapsone
 - statins
- ▶ Infections
 - leprosy
 - *Borrelia*
 - HIV, HTLV1
- ▶ Connective tissue diseases
 - Sjogren's syndrome
 - systemic lupus erythematosus
 - rheumatoid arthritis
- ▶ Metabolic
 - diabetes
- ▶ Paraneoplastic
 - lung, ovarian carcinoma
- ▶ Inherited
 - CMT 2 and X
 - familial amyloid neuropathies
- ▶ Vitamins
 - vitamin B12
 - vitamin E
 - pyridoxine toxicity
- ▶ Endocrine
 - hypothyroidism
- ▶ Paraprotein
 - myeloma
 - Waldenström's disease
 - benign monoclonal gammopathies

upper limb SNAPs. It is rare for sensory nerve studies to be completely normal in neuropathies with sensory symptoms, except in the difficult category of late onset, painful small fibre neuropathies, such as occur with restless legs.

The simplest and most frequently asked question of motor conduction studies (although not necessarily the easiest to answer) is whether or not there is evidence of demyelination. Protocols specifying agreed criteria for demyelination have been prepared for patients suspected as having GBS⁶ or CIDP⁷ and these are useful. Establishing that the patient has a clearly demyelinating neuropathy is crucial to the subsequent sequence of investigations. Interpretation of the pattern of demyelination is a rather specialised area best left to your neurophysiologist, but one that is very useful. Thus uniform demyelination rather favours an inherited neuropathy, whereas patchy findings with differences between nerves, and segments within a nerve, are more in favour of an acquired syndrome.^{8,9} F wave latencies are useful in the early stages of GBS for assessing proximal conduction slowing, and may indeed be the only abnormality early in the course of the disease.¹⁰ Some syndromes have peculiarly individual features; thus the demyelinating neuropathy associated with immunoglobulin IgM anti-myelin associated glycoprotein (MAG) antibodies is characteristically associated with prolonged distal motor latencies.

Another common clinical question in which the neurophysiologist is crucial is in determining whether the neuropathy is symmetrical and confluent or whether focal or multifocal features are present. In the case of an asymmetric

Box 7: First round screening tests

- ▶ Blood sugar
- ▶ Liver function tests
- ▶ Vitamin B12
- ▶ Paraprotein screen
- ▶ Thyroid function
- ▶ Full blood count
- ▶ Erythrocyte sedimentation rate, vasculitic screen

neuropathy affecting the upper limbs, is there is evidence of conduction block to suggest a diagnosis of multifocal motor neuropathy, as opposed to MND?¹¹ Such studies need to include assessment of proximal block by stimulating at Erb's point, which may not be done routinely. The multifocal pattern of involvement seen in vasculitic neuropathy can often be very helpfully separated from multiple entrapments or root lesions. In Miller Fisher syndrome or bulbo-spinal neuronopathy, the salient question might be whether the sensory action potentials reduced in size.

WHAT SCREENING TESTS SHOULD I PERFORM?

Box 7 shows a reasonable first screen for a new presentation of an axonal neuropathy without an obvious cause.

If no cause is found from the above and there are no clinical clues in the past medical history, it would be reasonable to delve further into the family history and try if possible to examine the relatives. Further tests are usually performed at this stage according to clinical clues that suggest more unusual or esoteric causes for neuropathy. An example might be the measurement of anti-Hu antibodies to detect occult chest or gynaecological malignancy.⁵ It is impossible to list all investigations that might be of use and it should be emphasised that these should be targeted to the clinical situation. After these second line tests most recent studies suggest that there will be at least 15% of patients for which no cause can be found.¹² Studies of this group suggest that some may be immune in origin and others unrecognised genetic neuropathies. The main clinical concern in patients that are deteriorating is the presence of a vasculitis restricted to the peripheral nerves. Such a diagnosis can only be made on nerve biopsy, but the yield from biopsy in the chronic idiopathic symmetrical neuropathies is very small. If the neuropathy is of recent onset and progressive, or if there is a suggestion of systemic disorder or raised erythrocyte sedimentation rate (ESR), biopsy should be considered. Otherwise continued follow up is wise. Anti-Hu antibodies are important, since their presence is closely associated with a paraneoplastic neuropathy¹³ and undisclosed malignancy usually of the lung or ovary.

CSF analysis

Cerebrospinal fluid (CSF) analysis is useful to distinguish immune mediated neuropathies such as CIDP or chronic immune mediated axonal neuropathies where the CSF protein is frequently notably raised. The presence of a significant pleocytosis in a subacute neuropathy should raise suspicion of other acute inflammatory neuropathies such as *Borrelia* or sarcoidosis.

Special tests

Genetic testing for neuropathy has thankfully mushroomed in recent years and has solved many diagnostic conundrums. The area is covered in detail by Reilly and Hanna.¹⁴ Another area

where tests have increased dramatically is in dysimmune syndromes, especially antibody testing. It is obligatory to diagnose paraneoplastic syndromes by antibody testing in patients with subacute sensory neuropathies, and in practice the net is often cast wider than this clinical indication. A wide range of other antineuronal antibody tests are also available for specific indications.

Anti-ganglioside antibodies are sought in patients with suspected MMN. Anti-GM1 IgM antibodies are present in around 50% of patients with this syndrome, so their absence does not exclude the diagnosis, but their presence is diagnostically helpful.

Anti-GQ1b IgG antibodies are a highly reliable marker for Miller Fisher syndrome where they are invariably present in acute phase sera. In the motor axonal variant of GBS, anti-GM1 and anti-GD1a antibodies are also frequently found, being present in over 50% of cases.

In chronic neuropathy syndromes, particularly those associated with IgM paraproteins, antibodies to MAG, sulfatide, and GD1b ganglioside are sought since they define rather discrete clinical phenotypes. In none of these latter syndromes does the presence of antibody predict a good response to treatment.

When should I do a nerve biopsy?

Sensory nerve biopsy has become established as a diagnostic procedure for the investigation of certain types of neuropathy over the last 30 years.¹⁵ The advent of genetic tests for many neuropathies has reduced the need for biopsy, but it remains the primary method of establishing a diagnosis of vasculitic neuropathy when histology is not available from elsewhere. A combined biopsy of nerve and muscle is usually advocated in cases of suspected vasculitis in order to increase the diagnostic yield.¹⁶ These biopsies usually involve the superficial peroneal or intermediate lateral nerves which allow access to muscle within the same incision. Since most vasculitic lesions occur in the epineurium a full thickness biopsy is generally preferred.¹⁷ The value of nerve biopsy has been addressed by a prospective study from Guy's Hospital. In this consecutive series of 50 sural nerve biopsies, management was altered in 60% and the diagnosis altered in 14% of cases. Such biopsies were considered to cause persistent pain at the biopsy site in as many as 33% of patients. This latter finding emphasises the need to restrict biopsy to carefully selected cases and ideally reserved for centres with expertise in the techniques involved.

Nerve biopsies can be helpful in the diagnosis of CIDP where histological identification of inflammatory cells or frank macrophage mediated demyelination on electron microscopy can be diagnostic. Unfortunately many patients

with CIDP do not have inflammatory cells in their sensory nerves and biopsy is probably unnecessary in patients with typical electrophysiology and clinical features of CIDP.¹⁸ The yield from biopsying chronic axonal neuropathies is very small and is probably not justified when a vasculitis seems unlikely. Patients with axonal neuropathy simulating an axonal form of CMT can occasionally turn out to have amyloid, especially if there are small fibre features. The diagnosis in these patients can frequently be made by looking for transthyretin mutations in most patients without recourse to biopsy, but if the genetics are unhelpful then a biopsy seems reasonable.

Authors' affiliations

H J Willison, Division of Clinical Neurosciences, Southern General Hospital, Glasgow, UK

J Winer, Department of Neurology, University Hospital Birmingham, Queen Elizabeth Hospital, Edgbaston, Birmingham, UK

REFERENCES

- 1 **Martyn CN**, Hughes RA. Epidemiology of peripheral neuropathy. *J Neurol Neurosurg Psychiatry* 1997;**62**:310–18.
- 2 **Schaumburg HH**, Berger AR, Thomas PK. *Disorders of the peripheral nerve*. Philadelphia: FA Davis, 1992:26–32.
- 3 **Hughes R**. Peripheral neuropathy. *BMJ* 2002;**324**:466–9.
- 4 **Mendell JR**, et al. Diagnosis and management of peripheral nerve disorders. In: *Contemporary neurology series*. Oxford: Oxford University Press. 2001:10–29.
- 5 **Hughes RAC**, Antoine JC, Honnorat J, et al. Paraneoplastic peripheral neuropathy associated with anti-Hu antibodies. A clinical and electrophysiological study of 20 patients. *Brain* 2002;**125**:166–75.
- 6 **Asbury AK**, Cornblath DR. Assessment of current diagnostic criteria for Guillain-Barre syndrome. *Ann Neurol* 1990;**27**(suppl):S21–4.
- 7 **Ad Hoc Subcommittee of the American Academy of Neurology AIDS Task Force**. Research criteria for the diagnosis of chronic inflammatory demyelinating polyradiculoneuropathy (CIDP). *Neurology* 1991;**41**:617–18.
- 8 **Fross RD**, Daube JR. Neuropathy in the Miller Fisher syndrome: clinical and electrophysiological findings. *Neurology* 1987;**37**:1493–8.
- 9 **Olney RK**, Aminoff MJ, So YT. Clinical and electrodiagnostic features of X-linked recessive bulbospinal neuronopathy. *Neurology* 1991;**4**:823–8.
- 10 **Kiers L**, et al. Quantitative studies of F responses in Guillain-Barre syndrome and chronic inflammatory demyelinating polyneuropathy. *Electroencephalography & Clinical Neurophysiology* 1994;**93**:255–64.
- 11 **Chaudhary V**, Corse AM, Cornblath DR, et al. Multifocal motor neuropathy: electrodiagnostic features. *Muscle and Nerve* 1994;**17**:198–205.
- 12 **Notermans NC**, Wokke JH, Fransen H, et al. Chronic idiopathic polyneuropathy presenting in middle or old age: a clinical and electrophysiological study of 75 patients. *J Neurol Neurosurg Psychiatry* 1993;**56**:1066–71.
- 13 **Graus F**, Bonaventura I, Uchuya M, et al. Indolent anti-Hu associated paraneoplastic sensory neuropathy. *Neurology* 1994;**44**:2258–61.
- 14 **Reilly MM**, Hanna MG. Genetic neuromuscular disease. *J Neurol Neurosurg Psychiatry* 2002;**73**(suppl II):ii12–21.
- 15 **Dyck PJ**, et al. Methods of fascicular biopsy of human peripheral nerve for electrophysiological and histological study. *Mayo Clin Proc* 1966;**41**:778.
- 16 **Said G**, Lacroix-Ciaudo C, Fujimura H, et al. The peripheral neuropathy of necrotizing arteritis: a clinicopathological study. *Ann Neurol* 1988;**23**:461–5.
- 17 **Said G**. Value of nerve biopsy? *Lancet* 2001;**357**:1220–21.
- 18 **Molenaar DS**, Vermeulen M, de Haan R. Diagnostic value of sural nerve biopsy in chronic inflammatory demyelinating polyneuropathy. *J Neurol Neurosurg Psychiatry* 1998;**64**:84–9.